



**Boston
Children's
Hospital**

Until every child is well™

Plastic and
Oral Surgery

nopco
An Employee
Owned Company

Deformational Plagiocephaly

A GUIDE TO DIAGNOSIS
AND TREATMENT

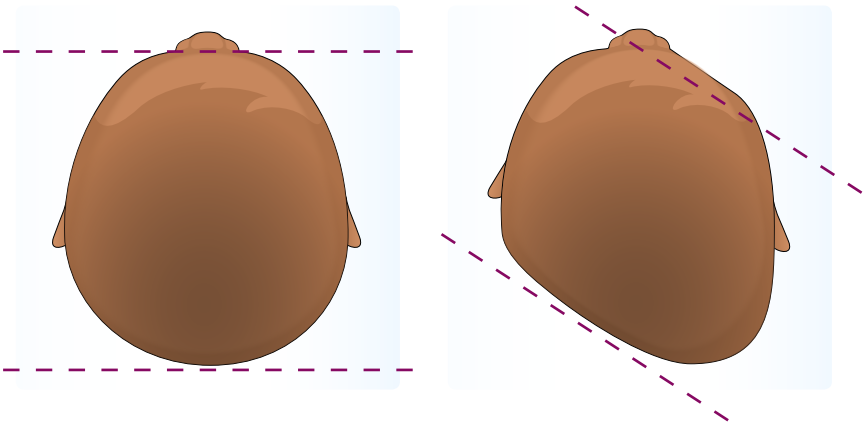
Introduction

In 1992, the American Academy of Pediatrics began to recommend supine sleeping for infants to reduce the incidence of Sudden Infant Death Syndrome (SIDS), and in 1994, the “Back to Sleep” campaign began. This campaign is credited with reducing the incidence of SIDS by over 50 percent.^{1,2} However, increased incidence of cranial deformities has been an unanticipated consequence of this change in sleep position. Recent studies estimate the incidence of cranial deformation, also referred to as “flat head syndrome,” is as high as 46 percent in otherwise healthy infants.³ Cranial deformation results from pressure on the head during its most rapid period of growth.

Mechanics of Cranial Deformation

As the brain grows at a rapid pace in early development, the cranial bones are pushed outward, similar to filling a balloon with water. When external force (such as a laying on a flat surface) limits expansion in a particular area, growth will continue in the areas of least resistance. However, unlike the soft surface of a water balloon that reverts to a round shape when external force is removed, the firm bones of the cranium retain deformation. The process of deformation occurs over time and is caused by restriction of growth.

Sample of Plagiocephaly (Misshapen Head)




Variations of Cranial Deformity

Head shape is commonly described using terms of latin origin. The four shapes described below are the most common abnormal head shapes a pediatrician will see. These four abnormal head shapes can be caused by either mechanical cranial deformation or by craniosynostosis, a condition caused by premature closure of a cranial suture (growth plate). Craniosynostosis is a pathologic process and usually requires surgery; therefore, it is important to differentiate the two phenomena.

Plagiocephaly

The term plagiocephaly describes an asymmetric head. This can be predominantly anterior (forehead flattening) or posterior (occipital flattening). Posterior deformational plagiocephaly is the most common abnormal head shape a pediatrician will see. Flattening is accompanied by anterior displacement of the ear, forehead, and in severe cases, the orbit and cheek.




Brachycephaly

Brachycephaly describes a short, wide head. The occiput flattens and there is bilateral widening in the temporo-parietal regions. In deformational brachycephaly, there is often bulging above the ears.




Asymmetric brachycephaly

Asymmetric brachycephaly is the combination of plagiocephaly and brachycephaly. It is characterized by asymmetric occipital flattening accompanied by bilateral parietal widening.



Scaphocephaly

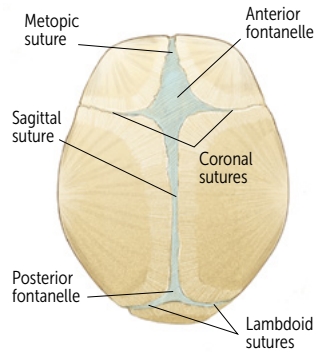
Scaphocephaly (also known as "dolichocephaly") is characterized by flattening of the sides of the head and elongation from anterior to posterior. Deformational scaphocephaly is most often seen in premature infants.



Differentiating Craniosynostosis from Cranial Deformation

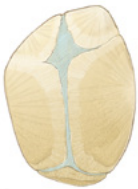Premature closure of the cranial sutures, or growth plates, is called craniosynostosis. Early closure limits bone growth perpendicular to the suture, causing growth restriction and abnormal head shape. Craniosynostosis is rare, with an incidence of 1/2,100–1/3,225 infants.^{4,5}

Each form of craniosynostosis is associated with a characteristic head shape that can usually be differentiated from deformation by physical examination. The differences between deformational head shape changes and craniosynostosis are detailed below. Further details may be found in the article by Dr. Gary F. Rogers titled, “Deformational Plagiocephaly, Brachycephaly, and Scaphocephaly Part 1: Terminology, Diagnosis, and Etiopathogenesis.”⁶ If craniosynostosis is suspected, prompt referral to a craniofacial plastic surgeon or neurosurgeon is indicated.



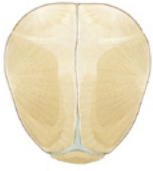Sagittal synostosis (synostotic scaphocephaly)

As the most common form of craniosynostosis,⁷ sagittal synostosis can be differentiated from deformational scaphocephaly common in premature infants by its characteristic forehead and low occipital bossing and the more severe degree of cranial narrowing.



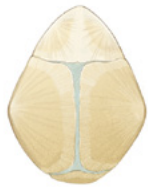Unilateral coronal synostosis (anterior plagiocephaly)

Unilateral coronal synostosis is the second most common form of craniosynostosis. The forehead is flat on the affected side, the orbit is shallow and drawn upward, and the nasal root deviates away from the affected side. With infants routinely sleeping on their backs, deformational anterior plagiocephaly is rare.



Bilateral coronal synostosis (synostotic brachycephaly)

Bilateral coronal synostosis is usually associated with syndromes, such as Apert Syndrome or Crouzon syndrome. The brachycephaly associated with bilateral coronal synostosis can be differentiated from common deformational brachycephaly by the severe degree of widening, compensatory vertical growth (“turricephaly”), and sometimes, the presence of syndromic features.



Metopic synostosis (trigonocephaly)

The metopic suture is the only suture to close in infancy or childhood. Metopic synostosis causes a protruberant forehead with recessed lateral orbital rims, hypotelorism, and bilateral parietal fullness. There is no deformational equivalent for trigonocephaly.



Lambdoid synostosis (posterior plagiocephaly)

This rare form of craniosynostosis can be mistaken for its very common deformational equivalent. However, the two causes of posterior plagiocephaly have different clinic features. From the vertex view, a patient with lambdoid synostosis has a trapezoid shaped head. The occiput is flat on the affected side, and there is contralateral occipital and forehead bossing. The ear shifts posteriorly, toward the affected suture, and there is prominence of the mastoid. Conversely, a patient with deformational plagiocephaly has a parallelogram shaped head. The occiput is flat on the affected side, the ear moves anteriorly, away from the affected area, and there is ipsilateral forehead bossing.

Risk Factors for Deformational Plagiocephaly

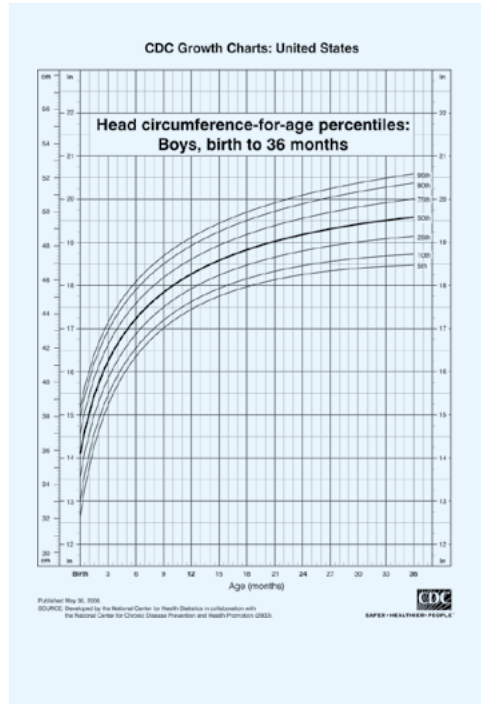
Understanding risk factors for deformational plagiocephaly is essential for prevention, diagnosis, and treatment. While supine sleeping is often blamed for causing cranial deformation, multiple risk factors are usually present in infants with plagiocephaly.

Risk factors include: ^{8,9}

- multiple gestation
- premature birth
- developmental delay
- first-born status
- male gender
- torticollis
- restricted movement while supine (such as in a carseat, swing, or Rock 'n Play)

Because torticollis (sternocleidomastoid muscle imbalance) is a strong risk factor for deformational plagiocephaly, primary providers should ask whether or not the infant has a head positional preference during the first well-baby visit.

A preferred head position, or difference in cervical rotation may be a sign of torticollis. Even in the absence of limited cervical rotation, positional preference is often associated with deformational plagiocephaly.



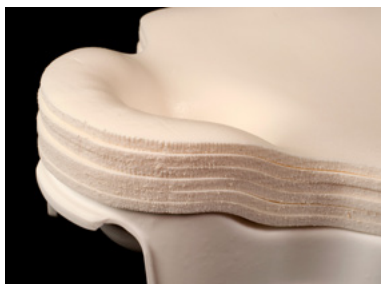Prevention and Treatment of Deformational Plagiocephaly

Given that cranial growth is necessary for shape deformation, growth is also needed to correct head shape. The growth rate of an infant's head is most rapid at birth, continuing through the first few months of life. By three months of age, the cranial growth rate declines and does so progressively over the first years of life. Standard CDC head circumference growth charts demonstrate the rate of change. Because correction relies on cranial growth, shape is most expeditiously and effectively corrected during periods of rapid growth early in life, regardless of the treatment modality employed.

Prevention

Measures to prevent cranial deformation should be employed immediately after birth and have been shown to reduce the rate of plagiocephaly by over half⁹. When possible, pressure on the back of the head should be avoided, such as by carrying baby facing toward the parent or by doing "tummy time." For infants old enough, supported sitting, such as in a Bumbo® Seat, avoids pressure on the head. When supine position is necessary, such as during sleeping, unhindered movement should be encouraged. This includes avoiding prolonged time in carseat, baby swing, and other carriers. In addition, alter position of items of interest frequently, such as by rotating toys from side to side or by alternating direction in the crib. It is important to establish a habit of parental involvement early.

Use of a contoured sleep surface may help prevent plagiocephaly. Numerous products are on the market, ranging from donut pillows to wedges to carseat inlays. Data on the effectiveness of these products is lacking, and items like donut pillows may pose a suffocation risk when used in the crib. For infants with multiple risk factors for plagiocephaly, the [PlagioCradle™](#) may be considered for prevention. The PlagioCradle is a modified foam sleep surface contoured for the infant's body and head that relieves pressure on the occiput while in the supine position.



Guided repositioning

While deformational plagiocephaly is increasingly more common, most cases are mild and can be treated with repositioning. Repositioning focuses on many of the same strategies described above for prevention of plagiocephaly. In addition, strategies to help eliminate neck rotational preference and direct pressure to the prominent side of the occiput are used to help direct growth. These maneuvers include tucking a small towel under baby's back and shoulder while restrained in a carseat and altering feeding position. For infants with torticollis, physical therapy should be used in conjunction with repositioning. A [guide for repositioning](#) can be downloaded from the NOPCO website.

PlagioCradle

In partnership with Boston Children's Hospital, Boston Brace developed the [PlagioCradle](#), an alternative sleep surface, custom fit to each patient using layers of foam. The concept of cradle treatment is based on the notion that if an infant's maturing head deforms against a flat surface, then a concave surface would enable the head to grow in a normal, rounded fashion. This foam is dense enough to maintain its form under the weight of the infant, yet is soft enough to remain comfortable during long hours of use. The infant's head rests in a concave space allowing unrestricted occipital growth. The neck is supported in an anatomically correct position by a semi-circular shape in the foam layers.



The PlagioCradle works best when started in the first two months of life. It is used for a minimum of 12 hours each day, or whenever the infant is supine. Once an infant is able to roll over (usually around three to four months of age), cradle therapy is discontinued. At this age, if needed, the patient is then able to begin helmeting as a means of correcting their cranial asymmetry.

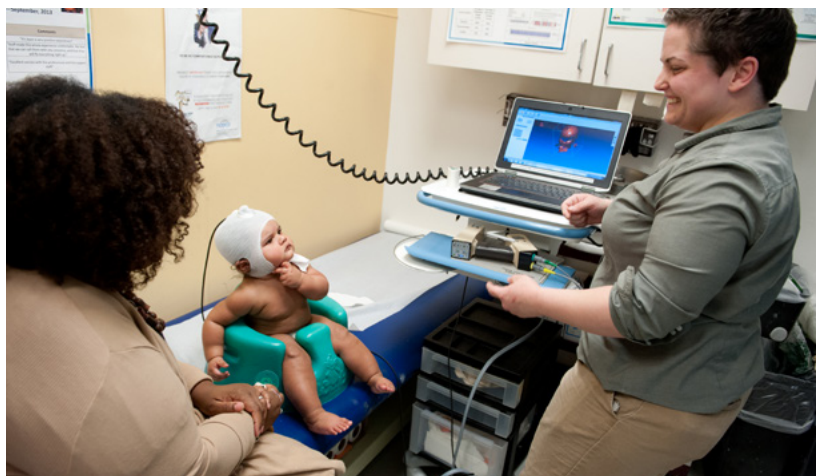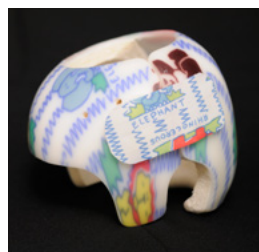The PlagioCradle has been shown to be effective for treatment of deformational plagiocephaly.^{10,11} The PlagioCradle is effective for treatment of plagiocephaly and there is growing data to support its use for scaphocephaly. Because the cradle can promote widening of the head, it is not recommended for brachycephaly.

Orthotic helmet therapy (Boston Band)

Numerous studies demonstrate effectiveness of orthotic helmeting for treatment of deformational plagiocephaly.^{12,13,14,15} An orthotic helmet works by restricting further asymmetric growth, guiding the flattened areas to grow into the empty space of the helmet. The orthotic device is made of

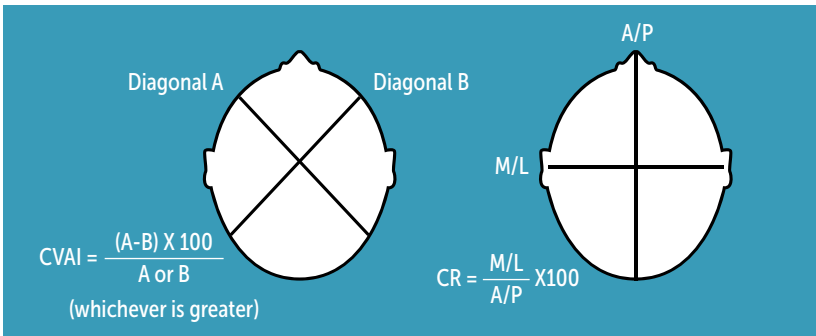
lightweight foam that is cut away in layers as the head grows. Helmets are custom made using cranial laser-scans taken during initial clinical visits. Helmets fit loosely and work by passively directing growth, rather than actively pushing on the cranium. Helmets are worn at all times, including sleep (a minimum of 23 hours/day), and are well-tolerated by most patients. The duration of helmet therapy at our center is typically 3–5 months.

Because the head grows fastest early in life, the sooner helmet therapy begins, the faster the rate of correction. Orthotic helmeting is usually started at 4 months of age or older, but may be considered as early as 3 months of age in select cases. Maximum improvement is achieved when started by 6–7 months of age,^{12,13} but good results are achieved within the first year of life. While improvement in cranial shape using orthotic helmeting has been documented in patients as old as 18 months,¹⁴ the rate of change will be slower and the degree of correction achieved smaller. In addition, our experience has been that older patients do not tolerate wearing the helmet as well as younger patients, making lengthy periods of helmeting challenging. For that reason, we recommend starting helmet therapy early.



NOPCO Clinical Outcome Data

Approximately 500 patients with abnormal head shape are treated at Boston-area [NOPCO clinics](#) annually. Clinical outcomes are regularly reviewed to ensure consistent quality care. Below are treatment outcomes for NOPCO patients with deformational plagiocephaly and brachycephaly, who completed treatment between January and May, 2013. Correction of plagiocephaly is measured using the Cranial Vault Asymmetry Index (CVAI), the percent difference between the diagonal dimensions of the head.¹⁶ Brachycephaly is measured using the Cranial Ratio (CR), the width to length ratio of the head.¹⁷



PlagioCradle

Thirty-five patients completed treatment with the PlagioCradle for deformational plagiocephaly. The mean treatment duration was 7.8 weeks, ending when the patient is able to roll out of the cradle. On average, patients started with a moderate degree of asymmetry and measured at the low end of mild asymmetry at the end of treatment. Note the slight widening of the head (CI) with cradle use, making the cradle inappropriate for treatment of brachycephaly.

Mean Characteristics and Treatment Outcomes for Patients with Plagiocephaly Treated with the PlagioCradle (January–May, 2013)

Patients (n)	Treatment Duration (weeks)	Initial CI (%)	Discharge CI (%)	Initial CVAI (%)	Discharge CVAI (%)
35	7.8	88.3 (normal)	90.1 (normal)	7.8 (moderate)	4.0 (mild)

Orthotic Helmet Therapy (Boston Band)

Two hundred and eighteen patients completed helmet therapy for plagiocephaly, brachycephaly, and asymmetric brachycephaly. On average, therapy was initiated at 6.5 months of age, with average duration in the helmet ranging from 12.1–14.7 weeks. On average, patients started with a moderate degree of deformity and measured at the upper limit of normal at the end of treatment.

Mean Characteristics and Treatment Outcomes for Patients Treated with the Boston Band (January–May, 2013)

Patients (n)	Age at Fitting (Months)	Treatment Duration (weeks)	Initial CI (%)	Discharge CI (%)	Initial CVAI (%)	Discharge CVAI (%)
112	6.7	12.3	–	–	7.7 (moderate)	3.5 (normal)
30	6.5	12.1	98.3 (moderate)	92.7 (normal)	–	–
76	6.4	14.7	96.9 (moderate)	92.1 (normal)	7.3 (moderate)	2.5 (normal)

- Plagiocephaly
- Brachycephaly
- Asymmetric brachycephaly

REFERENCES

1. National Center for Health Statistics, Centers for Disease Control and Prevention, DHHS. (2006). Deaths: Final data for 2003 [Electronic version].
2. Eunice Kennedy Shriver National Institute of Child Health and Human Development. (2006). Continuing Education Program on SIDS Risk Reduction. NIH Pub No. 06-6005. Accessed Dec. 6, 2013. http://www.nichd.nih.gov/publications/pubs/Documents/Cont_Educ_Prog_Nurses_SIDS_rev.pdf
3. Mawji A, Vollman AR, Hatfield J, McNeil DA, Sauvé R. The incidence of positional plagiocephaly: a cohort study. *Pediatrics*. 2013 Aug;132(2):298-304.
4. Lajeunie E, Le Merrer M, Bonaiti-Pellie C, Marchac D, Renier D. Genetic study of nonsyndromic coronal craniosynostosis. *Am J Med Genet*. 1995 Feb 13;55(4):500-4.
5. French LR, Jackson IT, Melton LJ 3rd. A population-based study of craniosynostosis. *J Clin Epidemiol*. 1990;43(1):69-73.
6. Rogers GF. Deformational plagiocephaly, brachycephaly, and scaphocephaly. Part I: terminology, diagnosis, and etiopathogenesis. *J Craniofac Surg*. 2011 Jan;22(1):9-16.
7. Shillito J Jr, Matson DD. Craniosynostosis: a review of 519 surgical patients. *Pediatrics*. 1968 Apr;41(4):829-53.
8. Oh AK, Hoy EA, Rogers GF. Predictors of severity in deformational plagiocephaly. *J Craniofac Surg*. 2009 Mar;20 Suppl 1:685-9.
9. Cavalier A, Picot MC, Artiaga C, Mazurier E, Amilhau MO, Froye E, Captier G, Picaud JC. Prevention of deformational plagiocephaly in neonates. *Early Hum Dev*. 2011 Aug;87(8):537-43.
10. Rogers GF, Miller J, Mulliken JB. Comparison of a modifiable cranial cup versus repositioning and cervical stretching for the early correction of deformational posterior plagiocephaly. *Plast Reconstr Surg*. 2008 Mar;121(3):941-7.
11. Seruya M, Oh AK, Sauerhammer TM, Taylor JH, Rogers GF. Correction of deformational plagiocephaly in early infancy using the plagio cradle orthotic. *J Craniofac Surg*. 2013 Mar;24(2):376-9.
12. Kluba S, Kraut W, Reinert S, Krimmel M. What is the optimal time to start helmet therapy in positional plagiocephaly? *Plast Reconstr Surg*. 2011 Aug;128(2):492-8.

13. Yoo HS, Rah DK, Kim YO. Outcome analysis of cranial molding therapy in nonsynostotic plagiocephaly. *Arch Plast Surg*. 2012 Jul;39(4):338-44.
14. Seruya M, Oh AK, Taylor JH, Sauerhammer TM, Rogers GF. Helmet treatment of deformational plagiocephaly: the relationship between age at initiation and rate of correction. *Plast Reconstr Surg*. 2013 Jan;131(1):55e-61e.
15. Couture DE, Crantford JC, Somasundaram A, Sanger C, Argenta AE, David LR. Efficacy of passive helmet therapy for deformational plagiocephaly: report of 1050 cases. *Neurosurg Focus*. 2013 Oct;35(4):E4.
16. Plank L, Giavedoni B, Lombardo J, et al. The use of a non-invasive laser data acquisition system to quantify and compare infant head shape with non-synostotic positional plagiocephaly. Paper presented at the Association of Children's Prosthetic-Orthotic Clinics Annual Meeting; Banff, Alberta, Canada; March 24-27, 2004
17. Hutchison BL, Hutchison LA, Thompson JM, Mitchell EA. Quantification of plagiocephaly and brachycephaly in infants using a digital photographic technique. *Cleft Palate Craniofac J*. 2005 Sep;42(5):539-47.



NOPCO locations

Massachusetts

NOPCO of Boston Children's Hospital
300 Longwood Avenue
Boston, MA 02115
617-355-6887

NOPCO of Boston Children's at Waltham
9 Hope Avenue, Suite 200
Waltham, MA 02453
781-216-1390

NOPCO of Boston Longwood Medical
431 Brookline Avenue
Boston, MA 02215
617-975-3854

NOPCO of Burlington
50 Mall Road, Suite G-10
Burlington, MA 01803
781-270-3650

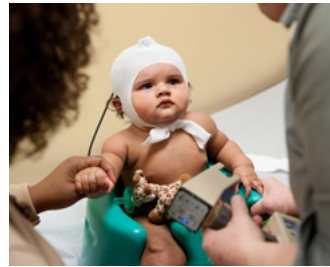NOPCO of Lawrence
25 Marston Street, Suite 201
Lawrence, MA 01841
978-688-7900

NOPCO of Weymouth, Stetson Building
541 Main Street, Suite 214
Weymouth, MA 02190
781-849-0247

New Hampshire

NOPCO of Exeter
1 Hampton Road, Suite 106A
Exeter, NH 03833
603-772-2388

NOPCO of Somersworth
224 Route 108, Unit A
Somersworth, NH 03878
603-343-2063



New Jersey

NOPCO of Neptune
3700 Route 33, Suite LL02
Neptune, NJ 07753
732-481-4500

NOPCO of New Jersey
585 Cranbury Road, Suite B
East Brunswick, NJ 08816
732-651-1223

**NOPCO of New Jersey Children's
Specialized Hospital**
150 New Providence Road
Mountainside, NJ 07092
908-233-3720 ext. 5299

NOPCO of Voorhees
200 Bowman Drive, Suite D279
Voorhees, NJ 08043
856-258-6712

Pennsylvania

NOPCO of Pennsylvania
3550 Market Street
Philadelphia, PA 19104
215-590-7702

**NOPCO of Pennsylvania
Children's Seashore House**
3405 Civic Center Blvd.
Philadelphia, PA 19104
215-590-7702

Boston Children's locations

Boston Children's Hospital
300 Longwood Avenue
Boston, MA 02115
617-355-7252

Boston Children's at Waltham
9 Hope Avenue
Waltham, MA 02453
781-216-2100

**Boston Children's Physicians
at Weymouth**
The Stetson Building
541 Main Street
Weymouth, MA 02190
781-216-3800



**Boston
Children's
Hospital**

Plastic and
Oral Surgery

Until every child is well™



Deformational Plagiocephaly

A GUIDE TO DIAGNOSIS AND TREATMENT